

# Forelimb Examination, Lameness Assessment, and Kinetic and Kinematic Gait Analysis



Darryl Millis, DVM\*, Krysta Janas, DVM

## KEYWORDS

• Thoracic limb • Forelimb • Lameness • Gait • Examination • Kinetics • Kinematics

## KEY POINTS

- Subtle forelimb lameness can be difficult to evaluate.
- A complete orthopedic examination is essential when diagnosing a forelimb lameness.
- Regardless of lameness lateralization, an examination should be performed bilaterally.
- The range of motion of joints should be assessed and recorded during each examination.

## INTRODUCTION

Forelimb lameness in dogs can be difficult to subjectively assess. Often, forelimb issues are bilateral, which can effectively reduce the asymmetry of gait abnormalities. Some practices have force plates or pressure walkways to objectively measure the amount of weight a dog places on each limb, whereas others must rely on a subjective visual lameness evaluation. In either case, a thorough orthopedic examination of the forelimb is necessary to determine the next appropriate diagnostic tools and the cause of the lameness.

### *Lameness Evaluation*

A good orthopedic examination begins by determining which limb or limbs are lame. Symmetry of the stance should be critically evaluated before ambulation for redistribution of weight. Dogs with forelimb discomfort and muscle atrophy often stand asymmetrically, with the less affected limb held closer to the midline, or they may shift their weight off the painful limb. The placement of the elbows can also be an important indicator of pain. Elbows held in adduction against the thoracic wall, with the distal

---

University of Tennessee College of Veterinary Medicine, 2407 River Drive, Knoxville, TN 37996, USA

\* Corresponding author.

E-mail address: [dmillis@utk.edu](mailto:dmillis@utk.edu)

Vet Clin Small Anim 51 (2021) 235–251  
<https://doi.org/10.1016/j.cvs.2020.10.001>

[vetsmall.theclinics.com](http://vetsmall.theclinics.com)

0195-5616/21/© 2020 Elsevier Inc. All rights reserved.

antebrachium and paw externally rotated, could indicate muscle contracture of the proximal forelimb. Elbows in abduction with the antebrachium internally rotated may be trying to alter weight-bearing in the elbows. Bilaterally affected dogs may shift their weight toward the pelvic limbs.

A flat, even surface with good traction is essential for gait evaluation. Both the walk and the trot should be observed from different angles (from both sides, the front, and behind the dog). Each limb strikes the ground separately at a walk, making it somewhat easier to distinguish which limb or limbs are lame. Although it is easier to observe and detect abnormalities at a walk, a subtle lameness may not be detectable at a slower speed because of reduced forces placed on the limb at a walk compared with a trot. Diagonal fore and pelvic limbs strike the ground simultaneously at a trot, making it somewhat more difficult to determine which limb is more lame. In the digital age, it is helpful to record the dog and watch the gait in slow motion. The adage, "down on the sound," can be used while evaluating a forelimb lameness. Dogs lift their head and transfer forces to the pelvic limb when the injured limb strikes the ground and lower their head when the unaffected limb is on the ground.<sup>1</sup> Dogs with forelimb lameness frequently have a shortened stride length and may have a shuffling-type gait because they maintain the joints in a more extended position with limited flexion of the elbows and carpi during gait.

A visual analog scale (VAS) or numeric rating score (NRS) may be used to describe limb function. The VAS consists of a measured line (usually 10 cm), with 1 end representing non-weight-bearing lameness and the opposite end representing an orthopedically sound dog. The observer makes a mark on the line based on their interpretation of the gait. The NRS assigns a numeric score to the lameness, with 0 being orthopedically sound, and the highest number on the scale representing a non-weight-bearing lameness.

It is important to remember that these measurements are subjective evaluations. Previous studies evaluating subjective gait analysis of induced hindlimb lameness have found that there is significant interobserver variability and low agreement when compared with objective gait analysis.<sup>2</sup> A recent article comparing interobserver and intraobserver agreement on VAS and NRS in dogs with elbow osteoarthritis (OA) found that both were similar before and after orthopedic examination.<sup>3</sup>

If the lameness is not obvious while walking or trotting, the dog can be walked down stairs or a hill. The braking required by the forelimbs during the descent may accentuate the issue. Dogs can also be walked over Cavaletti rails to evaluate elbow and carpal flexion.<sup>4</sup> OA of these joints can limit flexion, and dogs may compensate by swinging the limb out to clear the obstacle. If the dog is a competition or working dog, it is beneficial to watch them perform their specific tasks.

### ***Kinetics and Kinematics***

---

Kinetic gait analysis is performed with a force plate or walkway system. These tools can detect the peak vertical force (maximum force the dog places on each limb) and vertical impulse (area under the force-time curve). Force plates can also determine braking and propulsion forces. A study evaluating the agreement between NRS, VAS, and force plate analysis in dogs undergoing a right tibial osteotomy repair model found that agreement between the 3 analysis systems was most accurate when lameness was severe, but overall agreement was low.<sup>5</sup> This finding suggests that the ability to subjectively evaluate lameness is low unless the lameness is obvious. Force plate gait analysis is very sensitive and considered to be the gold standard, but subjective visual analysis should not be ignored.

Kinematic gait evaluation objectively assesses joint motion and stride characteristics, including joint range of motion (ROM), velocity, acceleration, swing time, stance time, and stride length in a 3-dimensional field. Evaluation of walking, trotting, and various exercises has been performed by applying reflective markers around individual joints and using a series of cameras to record and analyze the amount of flexion and extension. The approximate ROM of the shoulder, elbow, and carpus at a walk is 30°, 45°, and 90°, respectively. Trotting increases joint excursions by 5° in most joints, whereas the stifle increases approximately 20°. <sup>6</sup>

The kinematics of the major joints during various exercises were described by Carr and colleagues. <sup>7</sup> They found that the maximum flexion, extension, and ROM of the elbow and carpus, and shoulder flexion and ROM, significantly increased when walking up a 35° ramp or standard stairs compared with trotting on level ground. Others have found no changes in joint motion while ascending a 6.3° slope compared with walking. <sup>8</sup> Walking over low Cavalettis significantly increases elbow flexion. <sup>7,8</sup> Dogs with a fragmented medial coronoid process have decreased ROM of the elbow, carpus, and metacarpophalangeal joints of the affected limb. <sup>9</sup>

### **Initial Evaluation**

---

During initial evaluation of the forelimbs, dogs should be in a standing position with the limbs located squarely beneath them to accurately assess for muscle atrophy. An asymmetrical stance (eg, with 1 limb ahead of another) causes asymmetrical stretching of muscle bellies, which may give the false impression of muscle atrophy. The limbs are assessed for pain, inflammation, swelling, and anatomic asymmetry. Both hands should be used to palpate and compare the limbs simultaneously working in a proximal to distal direction.

The scapulae should be palpated simultaneously to assess for symmetry of muscle mass and prominence of the scapular spine. Next, assess the relative positions of the greater tubercles in comparison with the acromial processes of the scapulae. If muscle atrophy is present, there will be less muscle between the 2 bony prominences. This area is also evaluated for shoulder luxation by determining if one of the greater tubercles is asymmetrical compared with the contralateral limb.

The elbow is one of the most complex joints in the body. Both elbows should be carefully assessed for the presence of effusion in the craniomedial and caudolateral quadrants. Because there is also a significant amount of soft tissue (the flexors and extensors of the carpi and digits originate from the epicondyles) in a small area, it is difficult to appropriately evaluate for subtle joint effusion with the dog laying on its side. Having the dog in a standing position increases the amount of loading pressure on the joint, and palpating both joints simultaneously makes it easier to appreciate effusion. The craniomedial quadrant of the elbow can be identified by first finding the medial epicondyle and moving craniodistally and palpating the joint region just behind the pronator teres muscle. The caudolateral compartment can be located by identifying the space between the lateral epicondyle and olecranon of the ulna.

The shafts of the radius and ulna should be palpated for pain and swelling, working distally toward the manus. The long bones should always be assessed for pain to rule out panosteitis, hypertrophic osteodystrophy, and fractures in young dogs, and neoplasia or fractures in older dogs. The carpi should be evaluated for any effusion or anatomic asymmetry suggestive of fracture or subluxation of the carpal bones.

The carpus should be observed at a standing angle and evaluated for the presence of hyperextension. The carpus is the only joint in the body that has a greater angle than 180° while standing. <sup>10</sup> Dogs with greater than 200° of extension should be evaluated for carpal hyperextension injury. Varus or valgus positioning of the lower limb may

indicate an angular limb deformity. Carpal laxity syndrome and carpal flexural deformity may occur in puppies.

## ORTHOPEDIC EXAMINATION

After the standing evaluation is complete, and you have a general idea where the disorder is, the dog can be placed in lateral recumbency with the less affected (less lame) side up. Evaluating this side first will help prevent the dog from becoming tense and resistant as a result of pain and discomfort. Often, forelimb disease is bilateral, so this will also help prevent missing conditions in the contralateral limb. The examination may begin distally and work proximally, or vice versa. The important thing is to always perform the orthopedic examination the same way every time to avoid missing conditions.

### *Joint Measurements*

---

The ROM of the joints should be measured while performing an orthopedic examination. Joint measurement is performed with a goniometer. Full flexion and extension of joints are determined using specific landmarks, as previously described.<sup>10</sup> The joints of both limbs can then be compared with each other and a database to determine if disease is present, and if it is unilateral or bilateral. Remember that OA is one of the most common conditions diagnosed in older dogs, with approximately half of adult dogs having OA, usually in more than 1 joint,<sup>11</sup> and dogs with OA often have decreased ROM.

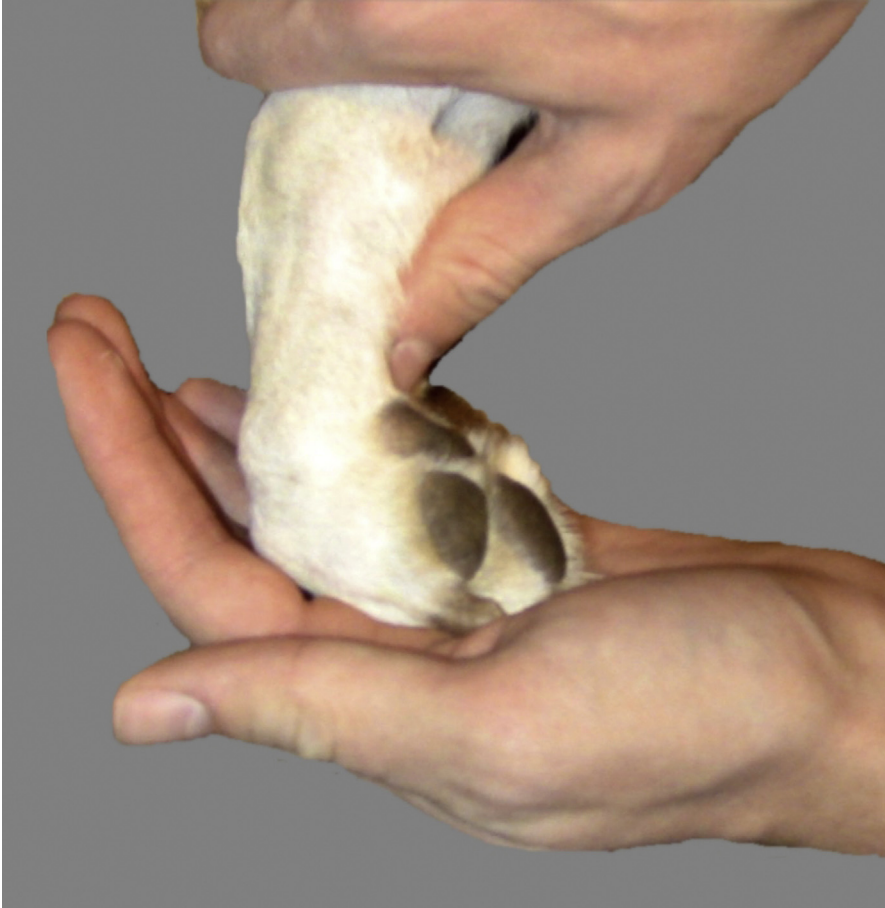### *Digits and Metacarpals*

---

The nails, interdigital space, and paw pads should be assessed for abnormalities and asymmetry. Abnormal wearing of the nails suggests neurologic conditions or trauma. The base of the nail should be evaluated for infections (paronychia) and tumors. Squamous cell carcinoma and melanoma, especially in darker dogs, are the most common tumors associated with the digits.<sup>12,13</sup> The toes should be spread apart to look for interdigital pyoderma, characterized by swelling, focal alopecia, pruritis, or nodules.<sup>14</sup> The digital and metacarpal pads are susceptible to abrasions, lacerations, cracking, thermal injury, corns, and foreign bodies. The paw pads of indoor dogs can also become soft if they are not frequently exercised, making them more likely to become sore if their exercise suddenly increases.

The digits can be flexed and extended as 1 unit, paying close attention to the dog for any signs of discomfort or a decreased ROM; if abnormalities are noted, the area should be assessed more closely (**Figs. 1** and **2**). The dewclaw (phalanx I) should not be overlooked if present. Owners may forget to trim this nail, and it can grow until it irritates the soft tissues. Sporting and working dogs are more prone to digit injuries, so each digit and joint should be palpated separately. The digits should be evaluated for soft tissue and joint swelling, decreased ROM, pain on palpation of the diaphysis of the phalanges or sesamoid bones, and instability/crepitus owing to fractures. The collateral stability of the interphalangeal and metacarpophalangeal joints should also be assessed by applying varus and valgus stresses to each joint. If abnormalities are noted, radiographs should be performed. OA is especially common in the digits of sporting and working dogs, and the interphalangeal and metacarpophalangeal joints can be swollen and painful and have a decreased ROM.

The common digital extensor, superficial digital flexor, and deep digital flexor tendons attach to extensor processes of the distal phalanges, the palmar surface of the base of the second phalanges of digits II–V, and the flexor tubercle on the palmar



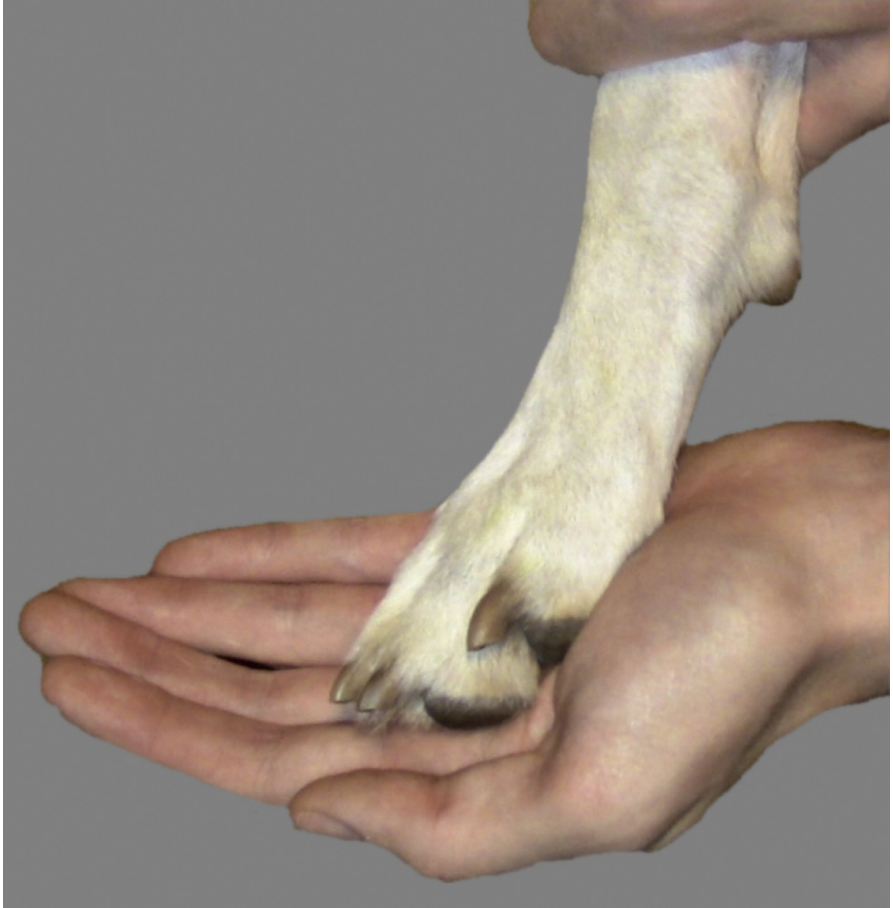**Fig. 1.** Flexion of the canine digits.

surface of the distal phalanges of the digits, respectively.<sup>15</sup> Flexor tendon injury most commonly affects the deep digital flexor tendon because it is more superficial at the level of the metacarpophalangeal joint and results in a dropped toe (hyperextension of the distal interphalangeal joint).<sup>16</sup> The nails of affected digits can be excessively long because they are not worn while the dog is walking. Valgus deformities of the digit are rare but can occur secondary to immune-mediated conditions (eg, rheumatoid arthritis) and give the appearance that the foot is externally rotated.

The metacarpal bones should be individually palpated to assess for swelling and pain, which can indicate fractures and occasionally neoplastic processes. Fractures occur most commonly in the body of the metacarpals.<sup>17</sup>

### ***Carpus***

The carpus should be flexed and extended while monitoring the dog for pain and abnormal ROM (**Figs. 3** and **4**). The ROM for a normal dog is approximately 200° of extension and 31° to 34° of flexion; however, this can be affected by breed.<sup>10,18</sup> In general, dogs with normal carpi should be able to touch their manus to the antebrachium

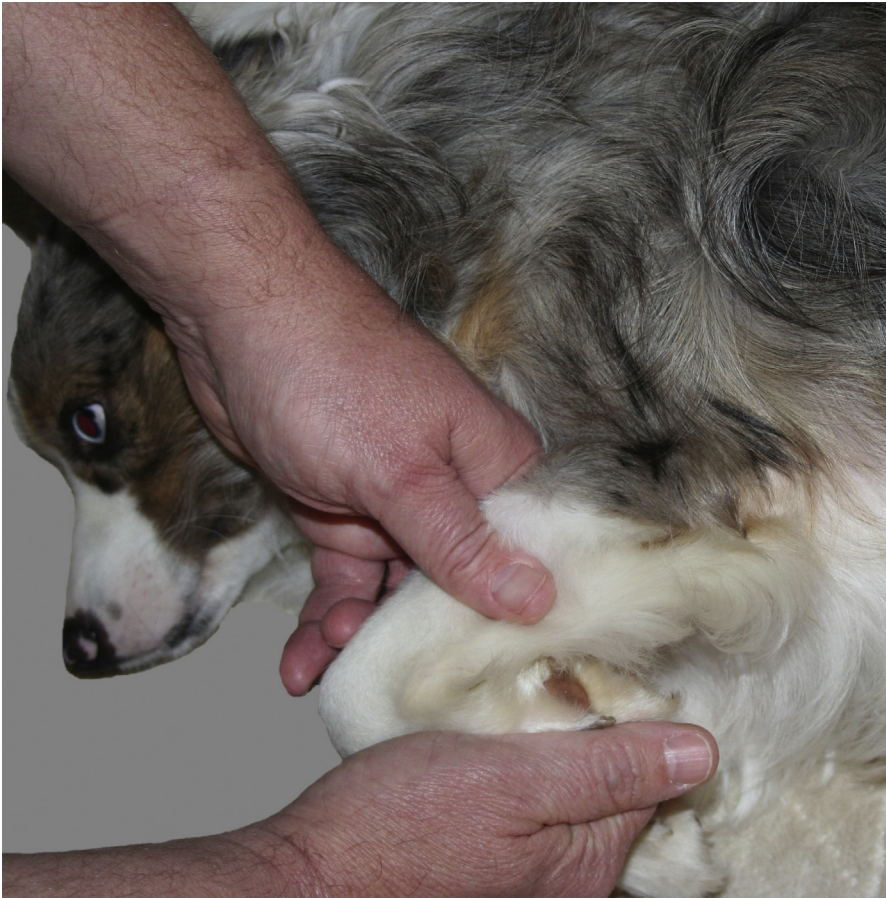

**Fig. 2.** Extension of the canine digits.

when the carpus is fully flexed. Often, older dogs will have a minor loss of flexion; however, this is usually not clinically relevant because dogs do not fully flex their carpus for normal daily function. Carpal hyperextension injury, with damage to the palmar fibrocartilage and carpal ligaments, occurs secondary to a jump, fall, or degenerative process.<sup>19</sup> Affected dogs have increased joint extension ( $>200^\circ$  at a stance), and often soft tissue swelling, joint effusion, and pain on manipulation of the carpus. If suspected, stress radiographs should be obtained. Special attention should be paid to the carpus of 4- to 7-month-old dogs to evaluate for carpal laxity syndrome and carpal flexural deformity.<sup>20</sup>

The carpus should next be extended and varus and valgus stresses applied to assess for collateral ligament injuries. There is more varus-valgus motion in the carpus than other joints. Approximately  $6^\circ$  to  $8^\circ$  of varus and up to  $10^\circ$  to  $14^\circ$  of valgus can be obtained in the extended carpus of normal Labrador retrievers.<sup>10</sup>

The radiocarpal, ulnar, numbered carpal, and accessory carpal bones should be individually palpated to assess for pain. Fractures of the carpal bones can occur as a result of trauma. Joint luxation can occur at the level of the proximal



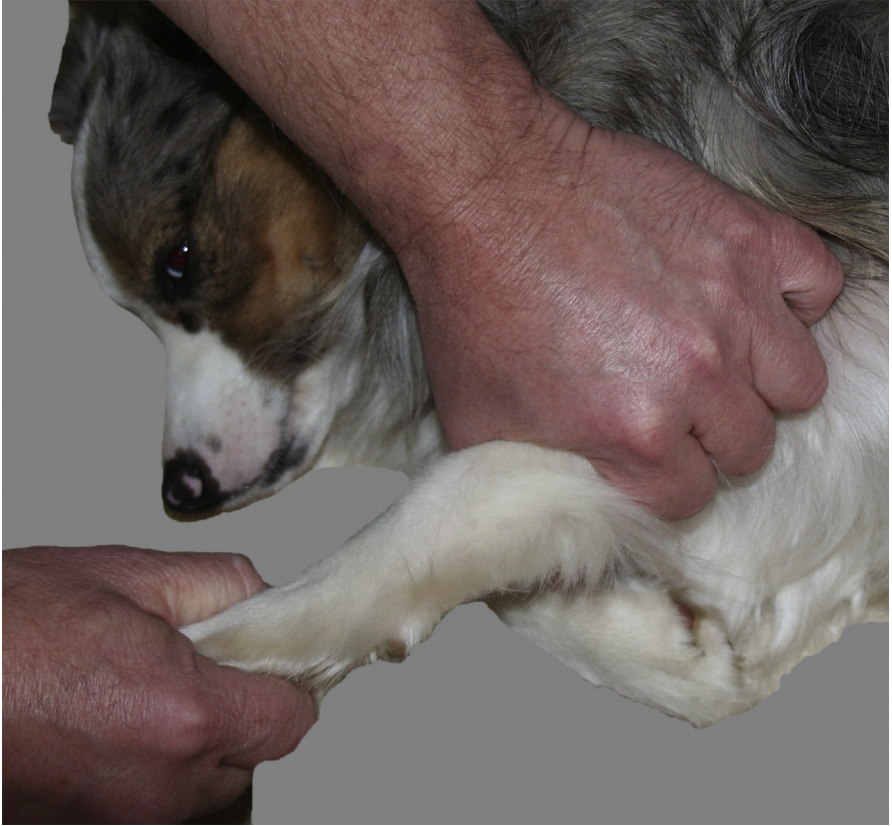**Fig. 3.** Flexion of the canine carpus.

(antebrachiocarpal), middle, or distal (carpometacarpal) carpal joint, so any asymmetry between the carpi should be noted. If suspected, stress radiographs should be obtained.

All of the carpal joints can develop arthritis, but OA of the antebrachiocarpal joint may be most noted because it normally has greater ROM than the other joints. Clinical signs may include pain and inflammation, joint effusion, decreased ROM, and/or bony deformation at one or more levels of the carpus.

### ***Radius and Ulna***

The radius and ulna should be palpated individually. Starting at the styloid process of the ulna on the caudolateral antebrachium, palpate proximally to the dorsal aspect of the olecranon while assessing for pain. The radius can be similarly palpated on the cranial aspect of the antebrachium from the antebrachiocarpal joint to the head of the radius. The abductor pollicis longus runs cranially through the radial and ulnar groove, obliquely crosses the radius and ulna, and inserts on the proximal aspect of the first metacarpal bone. This tendon should be palpated separately to assess for



**Fig. 4.** Extension of the canine carpus.

pain and a firm swelling at the distal medial aspect of the antebrachium, suggestive of stenosing tenosynovitis.<sup>21</sup>

Differentials for pain on palpation of the antebrachium vary based on location, age, and breed of the dog. Each bone should be palpated directly, as opposed to attempting to feel the bone through the muscles. Pain associated with the diaphysis of the radius and ulna of large and giant breed dogs, particularly German shepherds, is frequently associated with panosteitis. Discomfort at the metaphysis of large dogs may occur with hypertrophic osteodystrophy, or retained cartilage cores of the distal ulna, whereas older dogs are more likely have a neoplastic process in this location.<sup>22-24</sup>

Traumatic fractures can occur at any location along the radius and ulna, but most commonly occur at the middiaphysis to distal one-third of the radius and ulna in toy or miniature breed dogs.<sup>25</sup> The radius has minimal soft tissue coverage, and if a fracture is suspected, this area should be closely inspected to rule out an open fracture.

Angular limb deformity of the antebrachium is common when skeletally immature dogs have trauma to the distal ulnar or, occasionally, radial physis. As the normal distal radial growth plate continues to lengthen, the damaged ulna restricts normal growth, resulting in radial procurvatum and external rotation of the paw. This type of injury can also lead to incongruity of the elbow.<sup>26</sup>



## Elbow

---

The elbow should be flexed and extended to evaluate the ROM. The remaining joints in the forelimb should not be manipulated during the elbow examination, because this can cause confounding pain. Dogs without elbow disease should have 35° of flexion and 165° of extension.<sup>10</sup> Clinically, they should be able to touch their carpus to the greater tubercle of their shoulder during elbow flexion. When putting the elbow through these movements, monitor for resistance, discomfort, and crepitus, particularly at end flexion and extension. Any loss of ROM is associated with significant degenerative radiographic changes and decreased weight-bearing as measured on a force plate.<sup>27</sup> While extended, the elbow should have varus and valgus stress applied to evaluate the collateral ligaments.

Joint effusion is most easily palpated while standing; however, effusion can still be appreciated in dogs with moderate to severe disease when laterally recumbent. Both the craniomedial and the caudolateral joint compartments should be palpated. It is extremely important to include this aspect of the examination in young dogs to identify elbow dysplasia early, before the onset of clinical OA. Dogs with fragmented medial coronoid processes often have effusion in the craniomedial compartment, whereas dogs with ununited anconeal processes frequently have caudolateral effusion.

The bony prominences of the elbow should be individually identified and palpated for symmetry, pain, and stability. At the most proximal aspect of the elbow joint, the olecranon should be palpated. Moving distally, on the medial aspect of the elbow, the medial epicondyle is the first projection craniodistal to the tip of the olecranon; the flexor tendons arise from this area (Figs. 5 and 6). Just craniodistal to the medial epicondyle, the region of the medial coronoid process may be assessed. The medial coronoid can be difficult to accurately palpate because of the overlying soft tissue. To find the medial coronoid, the elbow should be flexed to relax the muscles and allow palpation of the medial coronoid process area. Discomfort during palpation of this area while supinating and pronating the antebrachium is suggestive of a fragmented medial coronoid process.<sup>28</sup>


On the lateral aspect of the elbow, the lateral epicondyle is craniodistal to the tip of the olecranon and should be in the same plane as the medial epicondyle (Fig. 7). The extensor tendons and the ulnaris lateralis originate from the lateral epicondyle. Asymmetry of the bony prominences can indicate traumatic luxation if the dog has an acute or traumatic history of forelimb lameness. Dogs most commonly develop a lateral elbow luxation, whereby the anconeal process slides over the lateral epicondyle, because it is significantly smaller than the medial epicondyle.<sup>29</sup> If the owners describe a more gradual onset or if the lameness waxes and wanes, anatomic abnormalities may be secondary to progressive degenerative joint disease.

The soft tissues surrounding the elbow are also susceptible to injury and should be evaluated, especially in dogs with a chronic forelimb lameness. All 4 heads of the triceps insert on the olecranon, and pain associated with direct palpation of the tendon may indicate a triceps insertion tendinopathy or olecranon fracture. Hygromas are commonly associated with the olecranon in large and giant breed dogs.<sup>30</sup> The biceps tendon inserts on the cranial aspect of the proximal radius and ulna, at the radial and ulnar tuberosities. To assess for a biceps insertion tendinopathy, the elbow should be extended to increase tension while the tendon insertion is directly palpated for pain.

## Humerus

---

As with the antebrachium, the humerus should be palpated from distal to proximal. The humerus is enveloped by muscles, so it may be difficult to palpate the shaft of

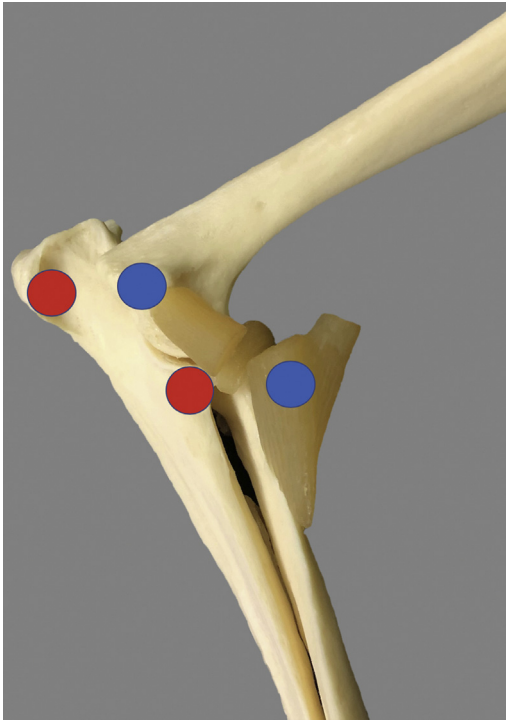


**Fig. 5.** Medial aspect of the left canine elbow. Dots are labeled from left to right. Red: olecranon; blue: medial epicondyle of the humerus; red: medial coronoid process of the ulna; blue: biceps tendon of insertion.

the bone without compressing muscle bellies. The radial nerve also crosses over the cranial aspect of the distal one-third of the humerus, and direct palpation of the nerve can cause discomfort.

Similar to the radius and ulna, the diaphysis of the humerus in young, large, and giant breed dogs is susceptible to panosteitis.<sup>22</sup> Pain associated with the proximal metaphysis in older dogs is frequently caused by osteosarcoma.<sup>31</sup>

Fractures can occur at any location but are more common in the middle and distal one-third of the humerus.<sup>32</sup> Significant pain on palpation of the humerus as well as fragment instability can be appreciated on examination. If a fracture is suspected, the neurologic function of the limb must be assessed to rule out radial nerve damage; this can be accomplished with toe-pinches and skin pricks to assess sensation. The lateral condyle of the humerus often fractures in young dogs after a fall or jump from a height.<sup>33</sup> Fractures of the medial condyle and bicondylar fractures are less frequent. These dogs are usually non-weight-bearing lame, with significantly decreased ROM and crepitus present on palpation and manipulation of the elbow. Spaniels, Labrador retrievers, Rottweilers, and other breeds are susceptible to incomplete ossification of the humeral condyle. If presented early, these dogs may have forelimb lameness with elbow effusion. However, if this pathologic condition is not corrected, they can develop unicondylar or bicondylar fractures of the humeral condyle.<sup>34</sup>



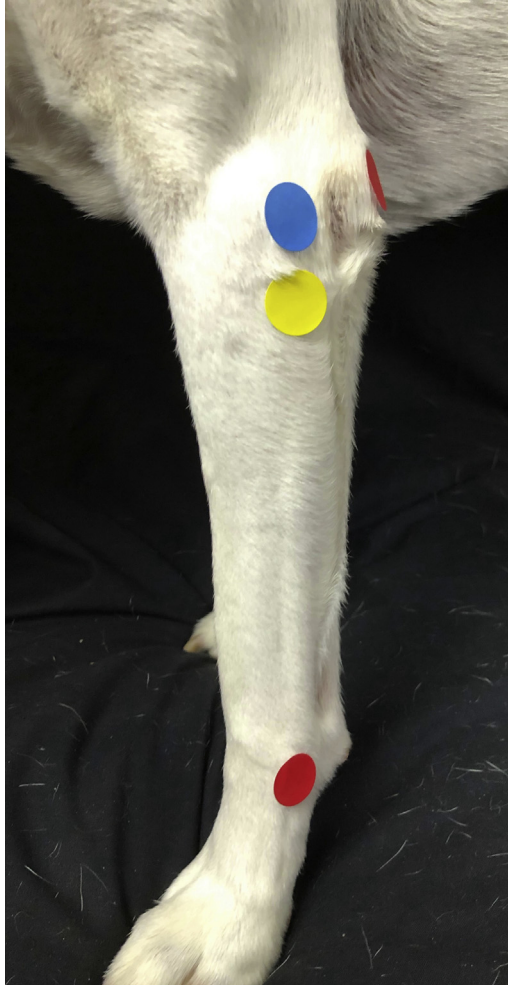**Fig. 6.** Bony prominences of the left canine elbow. Dots are labeled from left to right. Red: olecranon; blue: medial epicondyle of the humerus; red: medial coronoid process of the ulna; blue: biceps tendon of insertion.

### **Shoulder**

Passive ROM should be evaluated by flexing and extending the shoulder while assessing for limitations, pain, and crepitus. Normal dogs should have  $55^\circ$  of flexion and  $165^\circ$  of extension; however, a normal ROM does not mean that the shoulder is without issue.<sup>10</sup> Trigger points (muscle pain and fasciculations elicited by palpation) are commonly found during palpation of the muscles surrounding the shoulder, particularly the deltoideus, when shoulder abnormalities are present.

The shoulder is surrounded by muscles, tendons, and ligaments that act to stabilize the joint, and all are susceptible to injury. The associated soft tissues make it difficult to detect effusion, so assessment of the shoulder relies on manipulation of the joint and soft tissue palpation. Pathologic conditions affecting the shoulder structures include biceps tenosynovitis, supraspinatus tendinopathy, medial glenohumeral instability, and infraspinatus contracture. Working and performance animals seem to be particularly prone to injuring these tissues. Young, large breed dogs should be evaluated for osteochondritis dissecans.

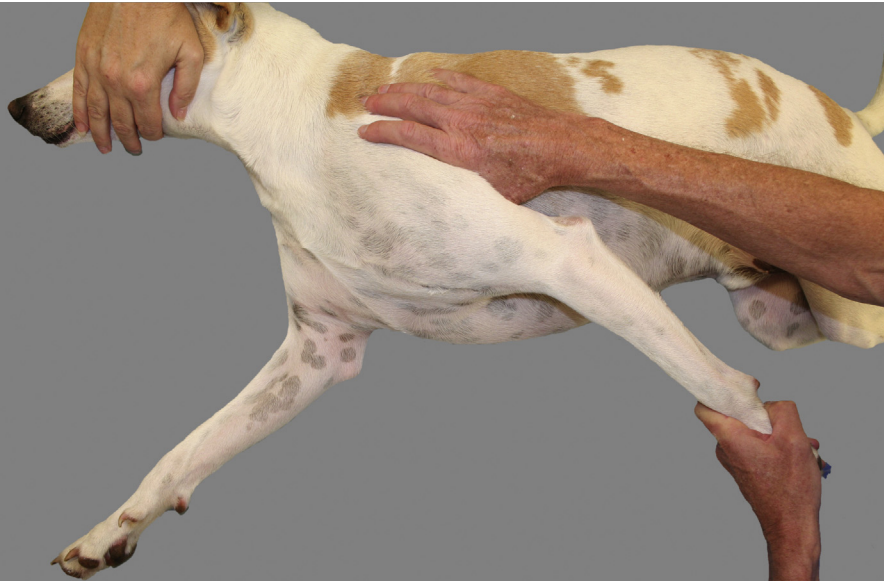The biceps tendon originates from the supraglenoid tubercle and can be identified as it crosses the joint just medial to the greater tubercle. The biceps tendon maneuver is used to detect biceps pain, suggestive of biceps tenosynovitis (Fig. 8). The biceps maneuver can be performed by flexing the shoulder while simultaneously extending the elbow; pain is associated with inflammation of the biceps and tendon sheath. The biceps tendon should also be palpated while performing this procedure to detect early pathologic condition or pathologic condition in stoic dogs.



**Fig. 7.** Lateral aspect of the left canine elbow and antebrachium. Proximal red: olecranon of the ulna; blue: lateral epicondyle of the humerus; yellow: head of the radius; red: styloid process of the ulna.

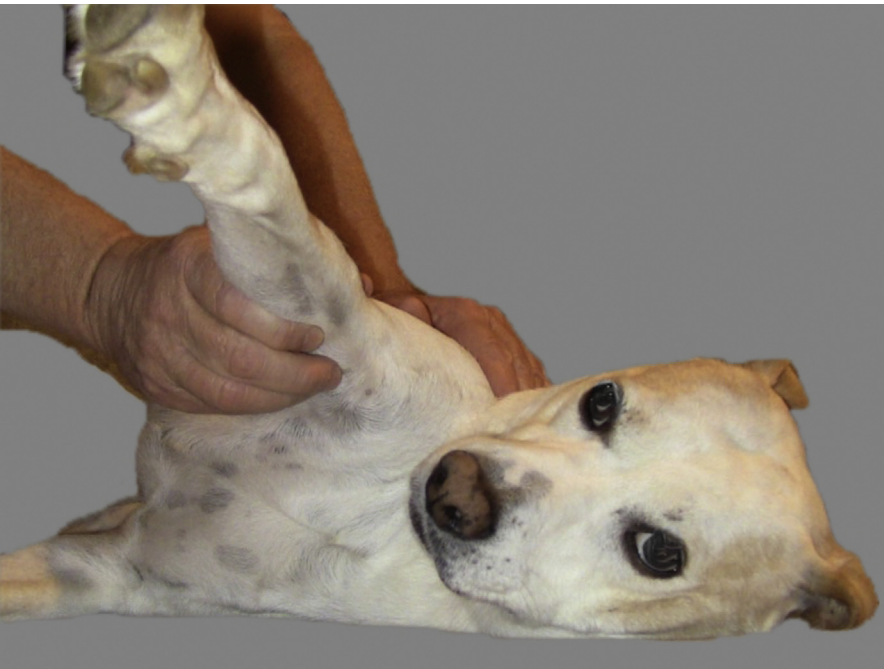The supraspinatus muscle lies cranial to the spine of the scapula and inserts on the greater tubercle of the humerus. Sporting dogs that overwork their shoulder by applying torsional stresses around the shoulder joint with rapid turning and pivoting seem to be at risk for injuring the supraspinatus tendon.<sup>35,36</sup> The tendon may feel firm and fibrotic with pain on shoulder flexion and palpation when compared with the contralateral limb. If untreated, the tendon is susceptible to develop chronic changes and calcification. Inflammation of the supraspinatus tendon can cause painful impingement of the biceps tendon. Flexion and internal rotation of the shoulder increase the amount of impingement and discomfort associated with this disease.

Medial shoulder instability (MSI) may result from injury to the medial glenohumeral ligament and/or subscapularis muscle and tendon. Similar to the supraspinatus tendon, it is most susceptible to damage when sporting dogs make rapid turns or jump down, and often these dogs have multiple muscles and tendons affected.



**Fig. 8.** Biceps maneuver.

Both structures are intraarticular and cannot be directly palpated. Historically, measurement of the shoulder abduction angle, the angle between the spine of the scapula and the lateral brachium during extension of the shoulder and elbow, has been recommended to diagnose MSI (**Fig. 9**).<sup>37</sup> If the shoulder is not extended, the angle of



**Fig. 9.** Shoulder abduction.

abduction will be falsely high. The angle of the affected limb is then compared with the contralateral limb, and if MSI is present, the angle of abduction will be significantly higher with pain at the end of abduction. Normal abduction angles should be approximately 30°; however, the angle should be compared with the contralateral limb. More recently, studies have found poor interobserver repeatability of goniometric measurements.<sup>38</sup> Many dog breeds that participate in sporting events (eg, border collies) are stoic and may only show discrete signs of discomfort, such as lip licking or a temporary pause in panting.

The infraspinatus muscle lies caudal to the spine of the scapula and inserts distal to the greater tubercle. Contracture of the infraspinatus muscle can develop and is most frequently diagnosed in hunting dogs. Presentation of these dogs is often biphasic. Acutely, there is pain and soft tissue swelling associated with the infraspinatus muscle, suspected to be caused by traumatic compartment syndrome; however, this stage is rarely identified, as signs resolve with conservative management. In the following weeks to months after the initial injury, the damaged infraspinatus undergoes fibrosis and contracture, and the muscle atrophies. The fibrosis of the muscle and tendon prevents full extension of the shoulder. Dogs have a distinctive gait and posture that make them easy to identify. At a stance, the shoulder is held in abduction, while the elbow is adducted against the body wall. The fibrosis and contraction results in abduction and external rotation of the paw, even when placed in lateral recumbency. During ambulation, there is a weight-bearing lameness, and the limb is circumducted with a flip of the paw just before placement.<sup>39</sup>

Luxations of the shoulder are uncommon but can occur in any direction. Traumatic luxations can occur in any breed, whereas toy and mini-breed dogs are susceptible to congenital shoulder laxity or malformation leading to luxation. On examination of these dogs, the spatial relationship between the acromion and greater tubercle is asymmetric compared with the contralateral limb regardless of the direction of luxation. Dogs with medial shoulder luxation may hold the elbow flexed and adducted, with the antebrachium held in abduction. Dogs with a lateral shoulder luxation may adduct the antebrachium.<sup>40</sup>

Osteochondrosis dissecans can develop on the caudal aspect of the humeral head in skeletally immature large and giant breed dogs.<sup>22</sup> Dogs with this condition are often in pain with either shoulder extension, or shoulder flexion and internal rotation. OA of the shoulder is common in adult and geriatric dogs; however, these dogs seem to do well clinically.

### **Scapula**

---

Although the scapula is covered by soft tissue, several bony prominences can be appreciated. The acromial process, spine of the scapula, and dorsal border of the scapula should be palpated, while monitoring for stability and the presence of crepitus. Fractures can occur anywhere along the acromion, glenoid, supraglenoid tubercle, scapular neck, scapular spine, and body of the scapula. A scapular luxation occurs when the serratus ventralis is torn from the thoracic wall or the scapula. These dogs are relatively easy to identify, with the scapula proximally displaced dorsal to the spine of the dog. The muscles cranial and caudal to the spine of the scapula, including the supraspinatus, infraspinatus, and long head of the triceps, should be assessed for firm, fibrous tissue.

During the examination, one should always keep in mind that there could be a primary or underlying neurologic component. The axillary region should be palpated as far medially and proximally as possible while the shoulder is abducted. Brachial plexus tumors are uncommon but can be a primary cause of forelimb lameness.

## SUMMARY

Thorough lameness and orthopedic examinations are essential to properly evaluate and diagnose a patient with a forelimb lameness. A systematic method of evaluation will result in a precise and efficient examination.

## CLINIC CARE POINTS

- Forelimb lameness is difficult to detect, so if there is any suspicion, a full examination and relevant workup are indicated.
- A complete orthopedic examination should always be performed bilaterally, regardless of where pain is identified.
- Always be systematic in your examination.
- A full orthopedic examination should be performed in young, growing dogs at their last vaccination visit to evaluate for elbow dysplasia and osteochondritis dissecans.
- A complete neurologic examination should be performed to rule out underlying neurologic disease.

## DISCLOSURE

No proprietary interest or funding was provided for this article.

## REFERENCES

1. Carr BJ, Dycus DL. Canine gait analysis. *Today Vet Pract* 2016;93–100.
2. Waxman AS, Robinson DA, Evans RB, et al. Relationship between objective and subjective assessment of limb function in normal dogs with an experimentally induced lameness. *Vet Surg* 2008;37(3):241–6.
3. Aulakh KS, Dongaonkar KR, Barnes K, et al. Influence of orthopedic examination on lameness scores and interobserver and intraobserver agreement in dogs with naturally occurring elbow osteoarthritis. *Vet Surg* 2020;49(3):455–62.
4. Weigel JP, Millis DL. Biomechanics of physical rehabilitation and kinematics of exercise. In: Millis DL, Levine D, editors. *Canine rehabilitation and physical therapy*. St Louis (MO): Elsevier; 2014. p. 401–30.
5. Quinn MM, Keuler NS, Lu Y, et al. Evaluation of agreement between numerical rating scales, visual analog scoring scales, and force plate gait analysis in dogs. *Vet Surg* 2007;36(4):360–7.
6. Allen K, DeCamp CE, Braden TD, et al. Kinematic gait analysis of the trot in healthy mixed breed dogs. *Vet Comp Orthop Traumatol* 1994;7(4):148–53.
7. Carr JG, Millis DL, Weng HY. Exercises in canine physical rehabilitation: range of motion of the forelimb during stair and ramp ascent. *J Small Anim Pract* 2013;54(8):409–13.
8. Holler PJ, Verena B, Dal-Bianco B, et al. Kinematic motion analysis of the joints of the forelimbs and hind limbs of dogs during walking exercise regimens. *Am J Vet Res* 2010;71(7):734–40.
9. Burton NJ, Dobney JA, Owen MR, et al. Joint angle, moment and power compensations in dogs with fragmented medial coronoid process. *Vet Comp Orthop Traumatol* 2008;21(2):110–8.
10. Jaegger G, Marcellin-Little DJ, Levine D. Reliability of goniometry in Labrador retrievers. *Am J Vet Res* 2002;63(7):979–86.
11. Millis DL, Tichenor MG, Hecht S, et al. Prevalence of osteoarthritis in dogs undergoing routine dental prophylaxis. Oral Presentation at: World Small Animal

- Veterinary Association World Congress proceedings; September 16-19, 2014; Cape Town, South Africa.
12. Henry CJ Jr, Brewer WG, Whitley EM, et al. Canine digital tumors: a Veterinary Cooperative Oncology Group retrospective study of 64 dogs. *J Vet Intern Med* 2005;19(5):720-4.
  13. Wobeser BK, Kidney BA, Powers BE, et al. Diagnoses and clinical outcomes associated with surgically amputated canine digits submitted to multiple veterinary diagnostic laboratories. *Vet Pathol* 2007;44(3):355-61.
  14. Mason IS. Canine pyoderma. *J Small Anim Pract* 1991;32(8):381-6.
  15. Evans HE, de Lahunta E. Guide to the dissection of the dog. In: Withrow SJ, MacEwen EG, editors. *The skeletal and muscular systems*. 7th edition. St Louis (MO): Saunders Elsevier; 2010. p. 32-9.
  16. Williams N, Payne JT, Tomlinson JL, et al. Deep digital flexor tendon injuries in dogs. *Compend Contin Educ Vet* 1998;19:853-60.
  17. Failing K, Matis U, Kornmayer M. Long-term prognosis of metacarpal and metatarsal fractures in dogs. *Vet Comp Orthop Traumatol* 2014;27(01):45-53.
  18. Laura LH, Geoffrey TF, Weh M. Comparison of range of motion in Labrador retrievers and border collies. *J Vet Med Anim Health* 2015;7(4):122-7.
  19. Whitlock R. Conditions of the carpus in the dog. *In Pract* 2001;23(1):2-13.
  20. Yardimci C, Sağlam M, Çetinkaya MA. Carpal laxity syndrome in forty-three puppies. *Vet Comp Orthop Traumatol* 2007;02(02):126-30.
  21. Grundmann S, Montavon PM. Stenosing tenosynovitis of the abductor pollicis longus muscle in dogs. *Vet Comp Orthop Traumatol* 2001;14(02):95-100.
  22. Scott H. Non-traumatic causes of lameness in the forelimb of the growing dog. *In Pract* 1998;20(10):539-54.
  23. Kushwaha RB, Aithal HP, Kinjavedakar P, et al. Incidence of skeletal diseases affecting long bones in growing dogs—a radiographic survey. *Intas Polivet* 2012;13(2):337-44.
  24. Dernell WS, Straw RC, Withrow SJ, Piermattei DL, Flo GL, DeCamp CE. Tumors of the skeletal system. In: *Small animal clinical oncology*. Philadelphia: WB Saunders; 2001. p. 262-96.
  25. Cooley S, Warnock JJ, Nemanic S, et al. Augmentation of diaphyseal fractures of the radius and ulna in toy breed dogs using a free autogenous omental graft and bone plating. *Vet Comp Orthop Traumatol* 2015;28(02):131-9.
  26. Krotscheck U, Böttcher P. Surgical diseases of the elbow. In: Johnston SA, Tobias KM, editors. *Veterinary surgery small animal*. 2nd edition. St Louis (MO): Elsevier; 2018. p. 836-55.
  27. Whitlock D, Millis DL, Odoi A. Can goniometry be used to detect the presence of lameness in dogs with chronic elbow osteoarthritis? *Vet Comp Orthop Traumatol* 2010;23(4):A14.
  28. Fitzpatrick N, Yeadon R. Working algorithm for treatment decision making for developmental disease of the medial compartment of the elbow in dogs. *Vet Surg* 2009;38(2):285-300.
  29. Mitchell K. Traumatic elbow luxation in 14 dogs and 11 cats. *Aust Vet J* 2011; 89(6):213-6.
  30. Angelou V, Papazoglou LG, Tsioli V, et al. Complete surgical excision versus Penrose drainage for the treatment of elbow hygroma in 19 dogs (1997 to 2014). *J Small Anim Pract* 2020;61(4):230-5.
  31. Culp WTN, Olea-Popelka F, Sefton J, et al. Evaluation of outcome and prognostic factors for dogs living greater than one year after diagnosis of osteosarcoma: 90 cases (1997-2008). *J Am Vet Med Assoc* 2014;245(10):1141-6.



32. Harari J, Roe SC, Johnson AL, et al. Medial plating for the repair of middle and distal diaphyseal fractures of the humerus in dogs. *Vet Surg* 1986;15(1):45–8.
33. Denny HR. Condylar fractures of the humerus in the dog; a review of 133 cases. *J Small Anim Pract* 1983;24(4):185–97.
34. Langley-Hobbs SJ. Fractures of the humerus. In: Johnston SA, Tobias KM, editors. *Veterinary surgery small animal*. 2nd edition. St Louis (MO): Elsevier; 2018. p. 820–36.
35. Soslowsky L, Thomopoulos S, Tun S, et al. Overuse activity injures the supraspinatus tendon in an animal model: a histologic and biomechanical study. *J Shoulder Elbow Surg* 2000;9(2):79–84.
36. Lafuente MP, Fransson BA, Lincoln JD, et al. Surgical treatment of mineralized and nonmineralized supraspinatus tendinopathy in twenty-four dogs. *Vet Surg* 2009;38(3):380–7.
37. Cook JL, Renfro DC, Tomlinson JL, et al. Measurement of angles of abduction for diagnosis of shoulder instability in dogs using goniometry and digital image analysis. *Vet Surg* 2005;34(5):463–8.
38. Jones SC, Howard J, Bertran J, et al. Measurement of shoulder abduction angles in dogs: an ex vivo study of accuracy and repeatability. *Vet Comp Orthop Traumatol* 2019;32(06):427–32.
39. Tangner CH, Taylor J. Acquired muscle contractures in the dog and cat. A review of the literature and case report. *Vet Comp Orthop Traumatol* 2007;02(02):79–85.
40. DeCamp CE, Johnston SA, Dejardin LM, et al. The shoulder joint. In: Brinker, Piermattei, and Flo's handbook of small animal orthopedics and fracture repair. 5th edition. St Louis (MO): Elsevier; 2006. p. 260–97.